

# Visualization and Quantification of Female Breast Morphology During Breast Reconstruction

Audrey L. CHEONG<sup>1</sup>, Gregory P. REECE<sup>2</sup>, Michelle C. FINGERET<sup>2,3</sup>, Fatima MERCHANT<sup>\*1,4</sup>

<sup>1</sup>Department of Electrical and Computer Engineering, University of Houston, Houston, TX, USA;

<sup>2</sup>Dept. of Plastic Surgery, The University of Texas MD Anderson Cancer Center, Houston, TX, USA;

<sup>3</sup>Dept. of Behavioral Science, The University of Texas MD Anderson Cancer Center, Houston, TX, USA;

<sup>4</sup>Department of Engineering Technology, University of Houston, Houston, TX, USA

<http://dx.doi.org/10.15221/14.021>

## Abstract

Breast reconstruction is an integral part of the breast cancer treatment process and has shown to positively impact the patient's psychosocial adjustment and quality of life. Three-dimensional (3D) visualization and quantification of the breast for different types of reconstruction procedures can allow for a better understanding of the changes in breast shape during the reconstruction process. It is important to realize that the reconstruction process can take as long as 18 - 24 months and the breasts typically change shape over the recuperation period following completion of any given surgical procedure. In this study we present a novel approach for monitoring and quantifying changes in breast shape using 3D surface images of the torso in conjunction with curvature measurements. The results of this study can help provide information to surgeons and patients about the dynamic changes in breast morphology occurring during the various stages of the reconstruction process. In our approach, we compare the curvature values of different regions of the breasts at longitudinal time-points of approximately 3-month intervals over the course of the reconstruction process. Results are shown for six patients. Three patients underwent the Transverse Rectus Abdominis Myocutaneous (TRAM) flap procedure for breast reconstruction, and the remaining three patients underwent implant-based reconstructions. Through our approach, we saw significant changes occurring along the lower pole of the breasts during the reconstruction process, which showed the importance of performing temporal evaluation in order to detect these changes.

**Keywords:** 3D image, breast surface normal, curvature analysis, visualization of shape, quantitative analysis

## 1. Introduction

Breast cancer is one of the most commonly diagnosed cancers among American women. According to National Cancer Institute (NCI), in 2014, an estimated 232,670 new cases of breast cancer were diagnosed in women in the United States. Breast cancer treatment typically involves complete or partial removal of the breast(s) resulting in permanent deformation of the breast. This deformation affects both self-esteem and body image of breast cancer survivors. Through breast reconstruction, the breast mound can be restored, which can enhance a patient's psychosocial and psychosexual well-being [1, 2].

After a mastectomy, a patient may be a candidate for immediate, delayed, or no breast reconstruction depending upon their body habitus and medical history. A patient's desires/preferences as well as financial situation also play an important role in determining type and timing of reconstruction. Typically, the reconstruction process may occur over a year or more. Sometimes, the contralateral natural breast has to be operated on as well in order to achieve an overall symmetrical appearance. It is important to recognize that the type of breast reconstruction that will give the best results varies from person to person.

The two main types of breast reconstruction are implant-based and autologous tissue-based (e.g., Transverse Rectus Abdominis Myocutaneous; TRAM flap). The long-term goal of this study is to develop a model for predicting outcomes from different breast reconstruction procedures, such as implants and tissue flaps, during the reconstruction process. As a preliminary step we were interested in monitoring the differences in breast curvature between implant and tissue flaps on various patients during the reconstruction process. In this study, we present an approach for visualizing and quantifying changes in breast morphology at longitudinal time-points for women receiving a breast implant or a TRAM flap. This information allows a better understanding of the changes in breast shape throughout the surgical process and the resulting outcome.

\* fmerchan@central.uh.edu; +1- 713- 743- 8292; [www.tech.uh.edu/faculty/merchant/](http://www.tech.uh.edu/faculty/merchant/)

## 2. Related Work

3D simulations of the breast are being developed by others as a surgical aid for the surgeon and as means of communication between the surgeon and patient. Current research is focusing on 3D imaging and simulation to address the uncertainties of breast surgery by providing visuals to surgeons and patients and to enable improved perception and understanding of changes in the morphology and shape of the breasts during breast reconstruction. Tepper et al [3] mention how 3D imaging can help provide guidance in choosing the tissue expander sizes during the reconstruction process. Patient and surgeon communication can also benefit, allowing a surgeon to use visual aids to give more accurate explanations of what can be accomplished through surgery. Chen et al [4] have developed a system that will allow surgeons to create or fit a model for a patient in order to help the patient visualize the most likely result from plastic or reconstructive breast surgery. Another model uses 2D images of previous patients to morph the 3D shape of the breast [5]. Roose et al [6] simulate implant modeling using Mass Tensor models that are based on continuum mechanics of linear elastic materials. Roose et al [7] conducted a comparative study of different simulation methods for subglandular breast implantation. To our knowledge, there has not been a study on longitudinal quantification of the female breast during the reconstruction process. The results of this study are to be used in development of models for more accurate prediction of surgical outcomes.

## 3. Data Acquisition

### 3.1. Imaging System

Three-dimensional surface images of breast cancer patients (IRB approved) were captured with the 3dMDTorso System (3dMD LLC., Atlanta, GA) prior to primary reconstructive surgery and at approximately 3, 6, 9, 12, and 18 months postoperatively. The 3dMDTorso enables the capture of 3D data clouds of 75,000 points. Each reconstructed surface image consists of a 3D point cloud, i.e., x, y, z coordinates, and the corresponding 2D color map. Only the frontal portion of the torso is imaged resulting in a surface mesh, which excludes the back region.

### 3.2. Study Sample

Six patients were studied; three patients had TRAM flap reconstruction and the other three had a breast implant reconstruction (see Table 1). The patients' ages ranged from 34 to 54 years and the BMI ranged from 20.4 to 39.6. All six patients began with temporary tissue expanders, which were later replaced with a TRAM flap or an implant. Patients A and B had unilateral TRAM flap procedures and patient C had a bilateral TRAM flap procedure. The three other patients (labeled D, E, and F) received breast implants; Patient D and F had implant reconstruction in both breasts while Patient E received an implant reconstruction in the left breast only.

Table 1. Demographic information about the reconstruction type, age, BMI, and operated breast(s).

Reconstruction Type	TRAM			Implant		
Patient	A	B	C	D	E	F
Age (years)	52	57	41	54	51	34
BMI	39.6	28.6	35.1	25.5	20.4	27.6
Operated Breast(s)	Left	Right	Both	Both	Left	Both

## 4. Methodology

### 4.1. Image Cropping

As a first step, the torso images were manually cropped to remove the neck, arms, legs and abdomen, leaving only the upper portion of the torso encompassing the breast as the region of interest (ROI). As shown in Figure 1, the ROI was defined from the vertical level of the sternal notch down to the lowest visible point of the breast. Horizontally, each breast was cropped individually from the longitudinal axis to the lateral point. These crops were performed using customized software developed in Java specifically for processing and analyzing the 3D surface images of breast cancer patients [8]. The left and right breasts were analyzed individually over the different time-points.

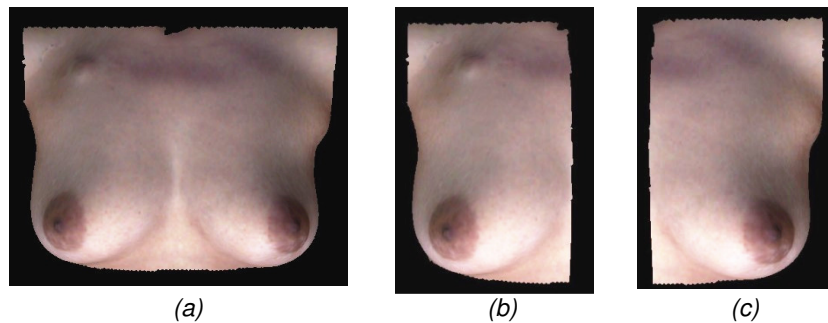


Figure 1. Image of torso (from the sternal notch to just below the IMF) with the neck and arms cropped. (a) Cropped image with both breasts (b) Cropped image of the right breast (c) Cropped image of the left breast

## 4.2. Curvature Analysis

Our approach was to analyze changes in the surface geometry of the breasts from the baseline image throughout the process of TRAM flap/implant reconstruction. The orientation of surface geometry can be defined by the direction of the surface normal, which is a vector that is perpendicular to the tangent plane to that surface at a given point. Based on the surface normal, the maximum angular difference between close lying points (within 10 mm) was recorded. The breasts were divided into radial sections based on the angle from the nipple location (which was manually estimated for breast mounds devoid of a nipple as a result of surgery) and the z coordinate. The divisions occurred at intervals of 60 degrees in the angular direction and the breast was split in half in the z direction based on the highest and lowest recorded z points, resulting in a total of 12 compartments as shown in Figure 2. A concatenated distribution of the angular differences combining all the 12 histograms was created for further analysis including measuring similarity based on the Bhattacharyya distance [9]. Figures 3 - 8 present results for the six patients, wherein the average value of the distribution for each section is displayed to show overall regional changes. The curvature analysis was done using Matlab (Mathworks, Natick, MA).

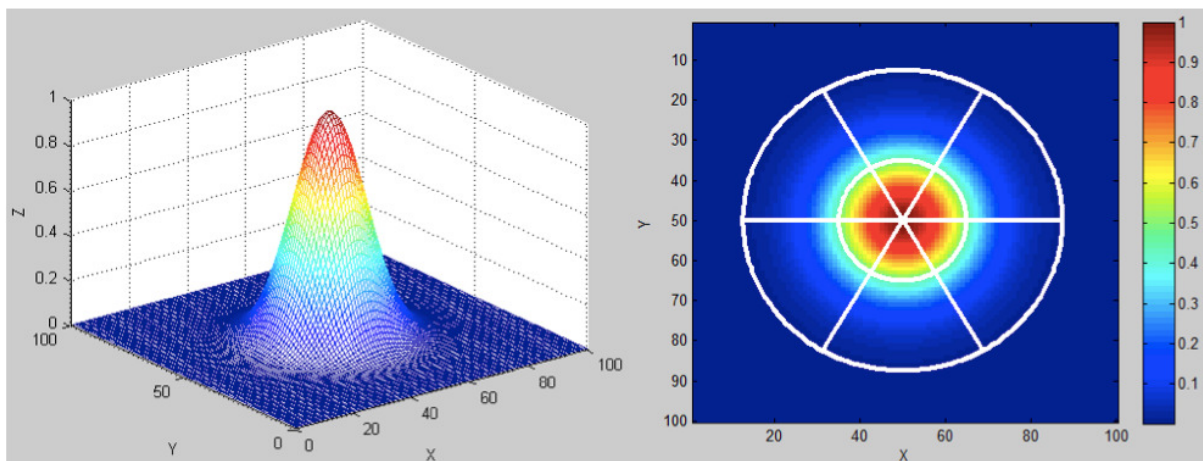


Figure 2. 2D Gaussian curve shown in 3D (left) representing a surface and shown on 2D plot (right). This example shows 12 compartments separated by the white lines at intervals of 60 degrees. The outer white circle represents the cropped region. The inner white circle is located at 0.5 along the z direction, which is halfway between the maximum and the minimum value.

## 5. Results

The upper pole of the reconstructed breast of Patient A (Fig. 3) showed relatively small changes in curvature throughout the reconstruction process with a tendency towards lower curvature, whereas the lower pole showed a gradual decrease in convexity starting at 8 months. At baseline (Fig.4), we observed maximal curvature at the lower pole of the natural breast for Patient B.

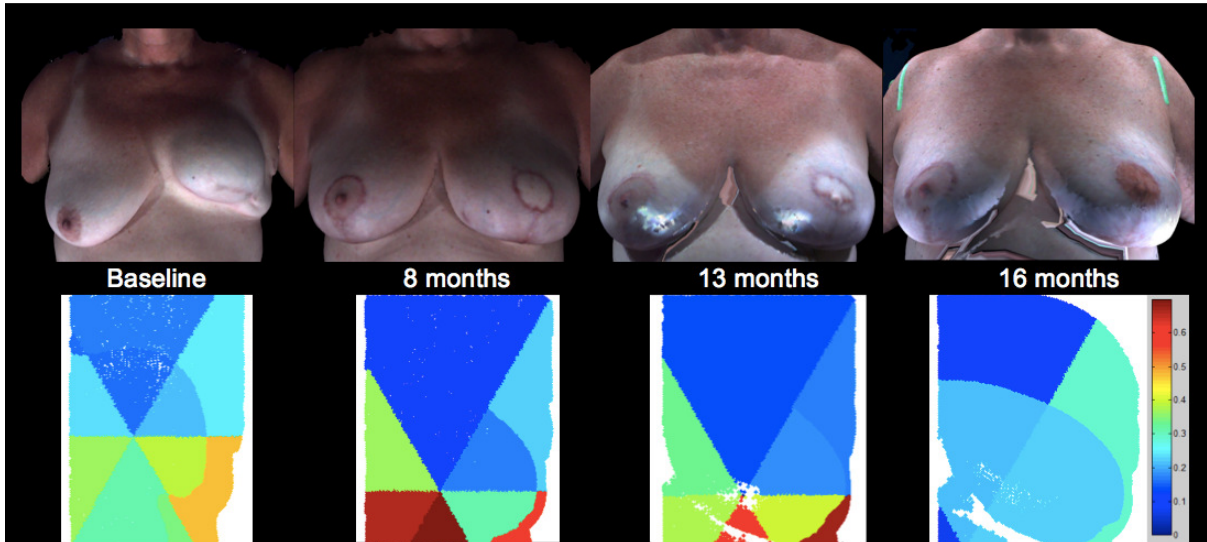


Figure 3. Patient A's 3D surface images of the TRAM reconstructed left breast from preoperative to 9 months postoperative (top row). 2D plots of the corresponding left breast analyses exhibited low (blue) to high curvature (red) (bottom).

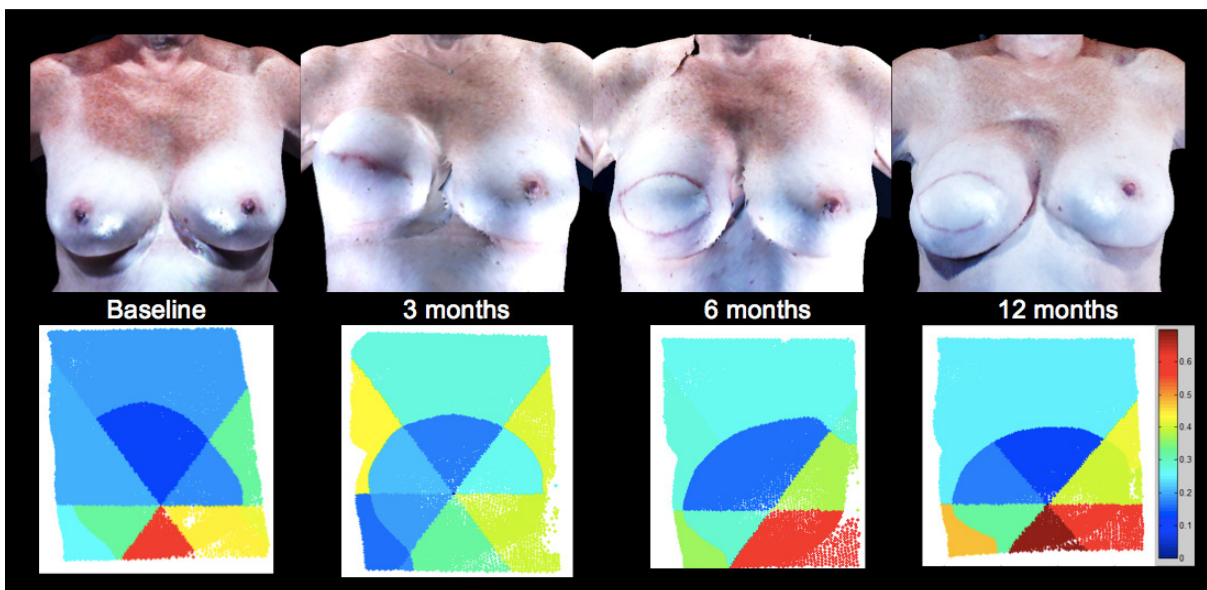


Figure 4. Patient B's images of the TRAM reconstructed right breast from baseline to 12 months postoperative (top row). The corresponding right breast analyses exhibited low (blue) to high curvature (red) (bottom).

However, the tissue expander significantly decreased the maximal curvature of the lower pole and the medial and lateral sides of the breast to some degree at 3 months. Six months after the TRAM flap was placed, the lower pole curvature was restored toward normal (compared to baseline) and then exceeded baseline at 12 months. Similarly, the medial and lateral breast areas of Patient B were restored towards normal at 6 months, but only the lateral part of the breast was restored to normal at 12 months. The medial pole of the breast exhibits higher curvature when compared to baseline. Patient C (Fig.5) showed a gradual settling of the breasts after the temporary tissue expanders were replaced with implants at baseline. The upper pole decreased in curvature while the lower pole increased in curvature.



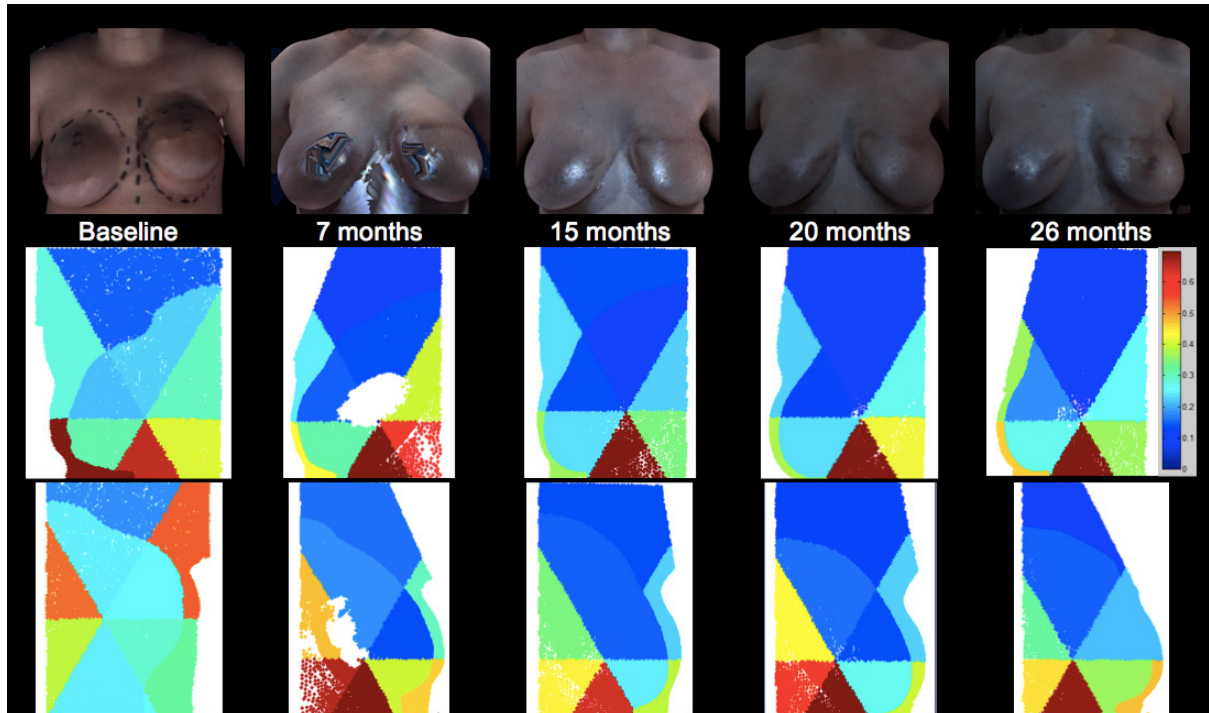


Figure 5. Patient C's Images of the TRAM reconstructed right breast from baseline to 18 months postoperative (top row). 2D plots of the corresponding right breast (middle row) and left breast (bottom row) analyses exhibited low (blue) to high curvature (red).

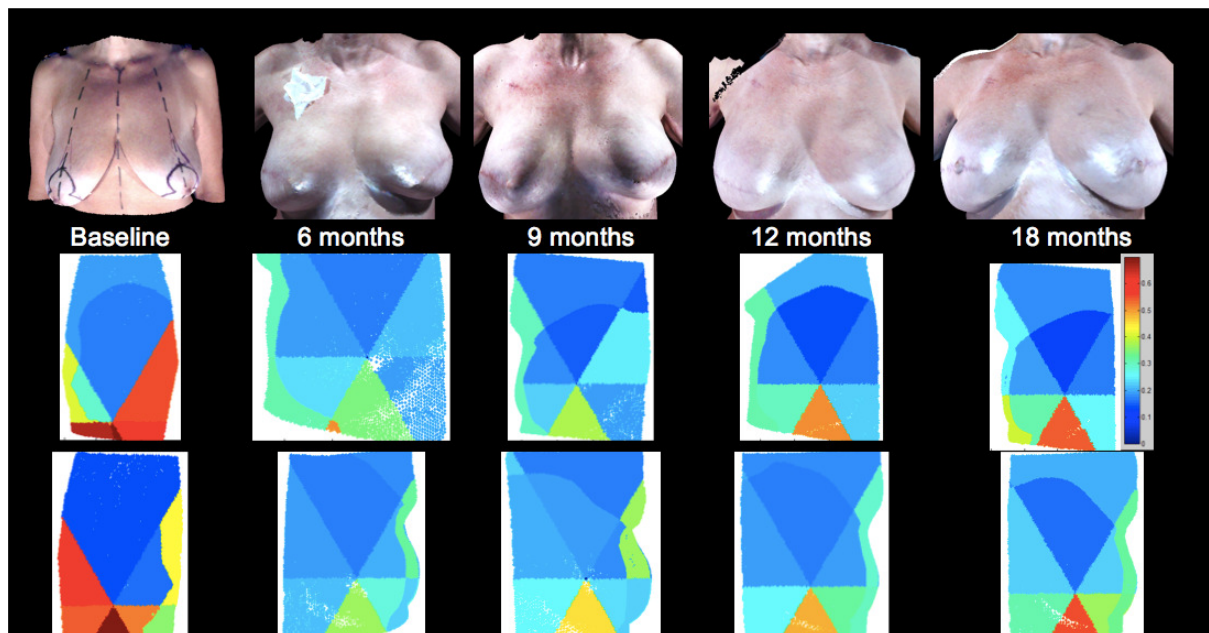


Figure 6. Patient D's 3D surface images of the implant reconstructed breasts from preoperative to 18 months postoperative (top row). 2D plots of the corresponding right breast (middle row) and left breast (bottom row) analyses exhibited low (blue) to high curvature (red).

After mastectomy, both breasts of Patient D (Fig.6) showed less curvature on the bottom pole at 6 months. During tissue expansion, the lower pole gradually increased in curvature while the upper pole appeared to decrease slightly in curvature. Patient E (Fig.7) had high curvature in the upper pole at baseline. At 3 months, the tissue expander is replaced with an implant and the upper as well as the lower regions appear to decrease in curvature. The lateral pole also decreases in curvature. Patient F (Fig.8), who initially started with tissue expanders that were later replaced with implants in both breasts, had high curvature in the lower pole. The curvature in the lower pole gradually decreases over the course of 21 months. The lateral parts of both breasts also decrease in curvature.

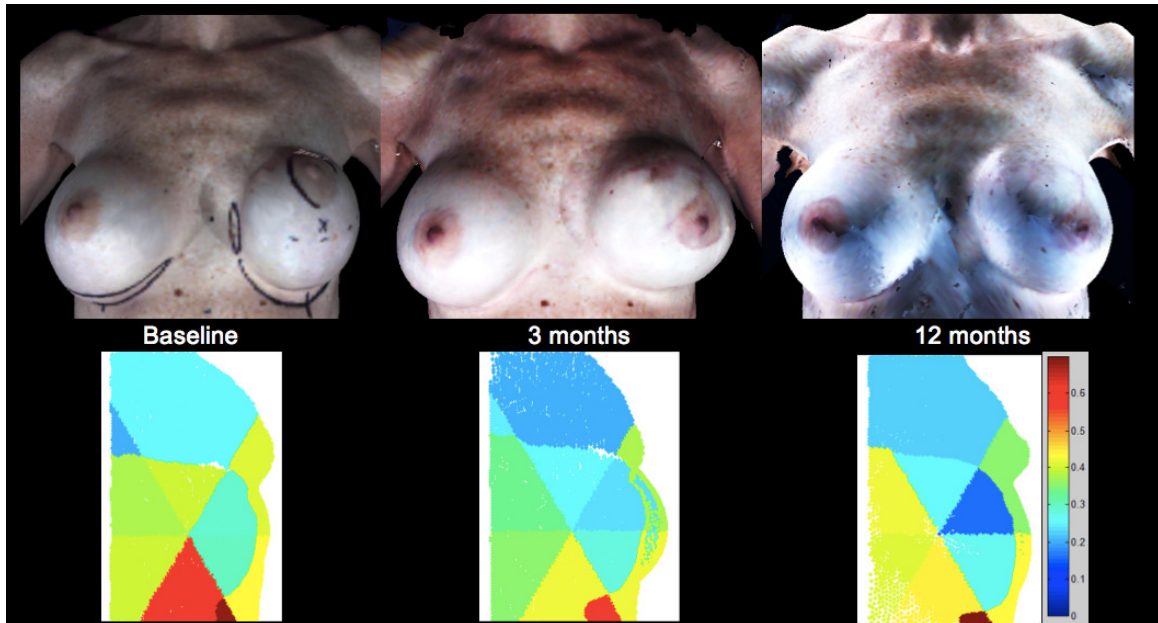


Figure 7. Patient E's images of the implant reconstructed left breast from baseline to 12 months postoperative (top row). 2D plots of the corresponding right breast analyses exhibited low (blue) to high curvature (red) (bottom).

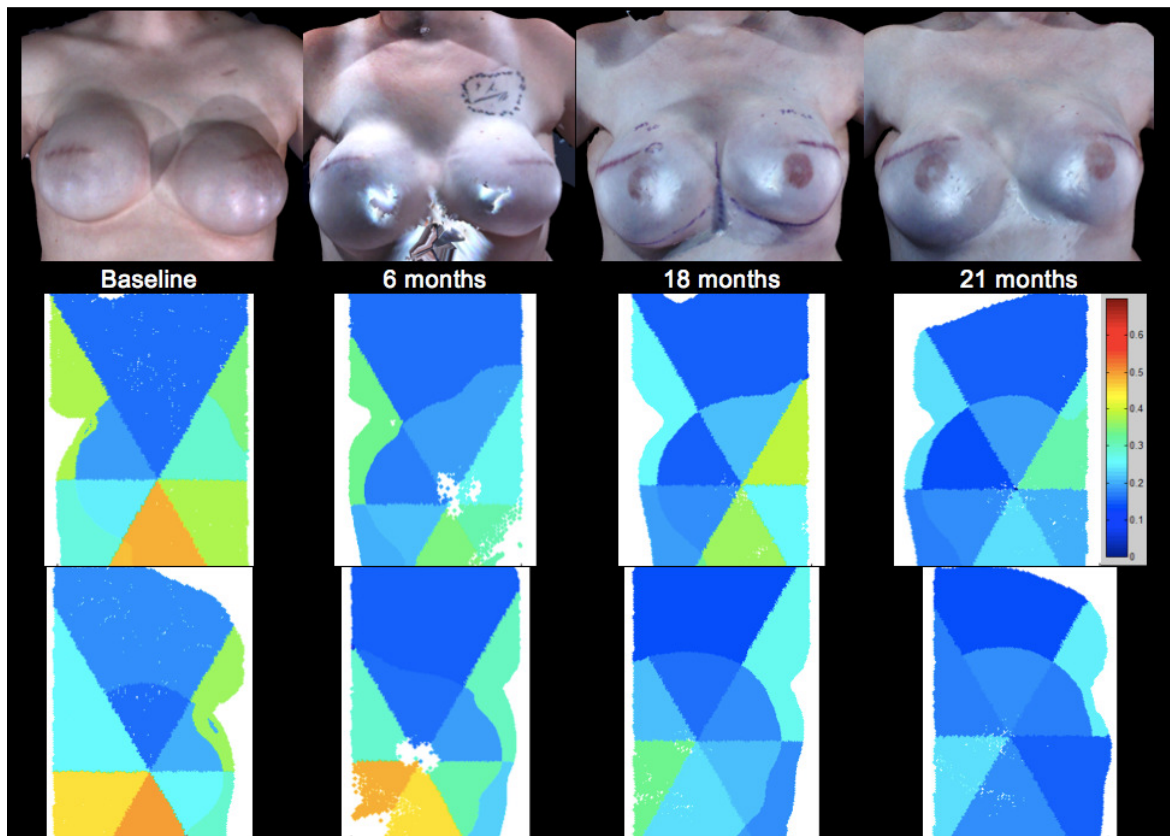


Figure 8. Patient F's images of the implant reconstructed breasts from baseline to 21 months postoperative (top row). 2D plots of the corresponding right breast (middle row) and left breast (bottom row) analyses exhibited low (blue) to high curvature (red).

To quantify the changes in breast morphology, the histograms of the angular differences at each time point for each breast were compared using the Bhattacharyya distance to the 3D surface image with the temporary tissue expander (see Table 3). The base image (visit 1) compared to itself has the value of 1, and it can be seen in Figure 9 that the similarity decreased with time. The similarity trend was similar between the patients who received TRAM flaps and the patients that received implants except for Patient A, who had a significant decrease in similarity at visit 4.

Table 2. Similarity measure based on the Bhattacharyya distance for the left and right breasts at different time points relative to baseline (0 months).

Procedure		TRAM Flap						Implant					
Patient		A		B		C		D		E		F	
Breast		Right	Left	Right	Left	Right	Left	Right	Left	Right	Left	Right	Left
Visit	1	1	1	1	1	1	1	1	1	1	1	1	1
	2	0.79	0.82	0.85	0.94	0.86	0.82	0.83	0.88	0.96	0.92	0.79	0.89
	3	0.82	0.80	0.85	0.94	0.84	0.76	0.80	0.89	0.95	0.87	0.85	0.82
	4	0.61	0.54			0.82	0.80	0.79	0.88			0.83	0.79
	5					0.83	0.81						

NOTE.— Visit 1 begins with the tissue expander case. It may not be the first image taken of the patient. Both patients B and D had tissue expanders beginning with their second images so their first images are not considered here.

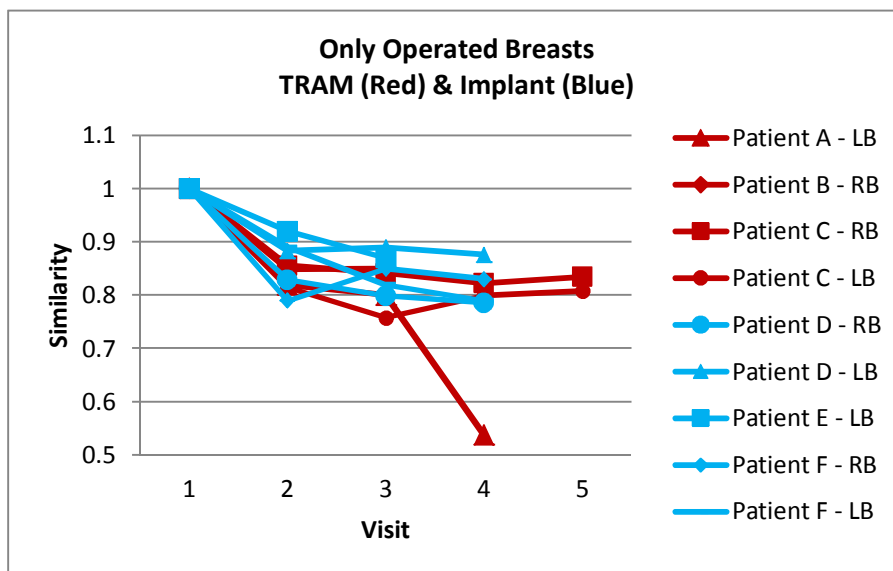


Figure 9. Plot of similarity based on the Bhattacharyya distance for the operated breasts versus visits. The red lines indicate TRAM procedures and the blue lines indicate implant procedures.

## 6. Conclusion

Longitudinal quantification of the female breast during breast reconstruction is an important preliminary step towards designing a model that will more accurately predict outcomes. Prior work focused on predicting only the final outcome through manual modeling or objective modeling based on images of previous patients and Mass Tensor models. Our approach measured curvature in different regions of the breast at different time-points during the reconstructive process for each patient. Through this study, we identified significant curvature changes in the lower pole during breast reconstruction for these patients. The tissue expander generally increases curvature in the upper pole of the breast and reduces curvature in the lower pole. Over time, after the tissue expander is replaced with a TRAM flap or implant and as edema resolves, the tissue settles and accommodates to gravitational forces that pull the breast downward and an increase in curvature is observed in the lower pole of the breast. However, for Patient F, after exchanging the tissue expanders with implants, the breasts actually recede over time leading to low curvature values in the lower half. Further analysis of these intermediate outcomes will contribute towards understanding the dynamic changes of the breast during breast reconstruction and predicting a more accurate final outcome.

## 7. Future Work

Future work includes incorporating automatic fiducial point detection and cropping to achieve a more robust evaluation of the data from different time points and exploring other methods of temporal quantification of the breasts. We further want to study how demographics (e.g. age and weight), may play a role in surgical outcomes over time with reconstruction as well as associations between surgical outcomes and psychosocial outcomes (e.g., quality of life, body image). The results of this study will contribute towards the design of a decision support system for breast cancer patients. While the similarity plot based on Bhattacharyya distance showed similar trends between patients who underwent a TRAM procedure and patients with an implant procedure, we want to explore additional options of comparing the two procedures that may show different trends.

## Acknowledgements

This work was supported by a NIH grant 1R01CA143190-01A1 (PI: Mia Markey) and the National Science Foundation Graduate Research Fellowship under Grant No. DGE-1144207 (Audrey Cheong). P. Garvey, M.D., and M. Clemens, M.D. of the Department of Plastic Surgery at The University of Texas MD Anderson Cancer Center generously provided the patient data used in this study.

## References

- [1] E. Elder, Y. Brandberg, T. Björklund, R. Rylander, J. Lagergren, G. Jurell, M. Wickman, and K. Sandelin, "Quality of life and patient satisfaction in breast cancer patients after immediate breast reconstruction: a prospective study," *The Breast*, Vol. 14, No. 3, 2005, pp. 201–8.
- [2] S. Al-Ghazal, L. Fallowfield, and R. W. Blamey, "Comparison of psychological aspects and patient satisfaction following breast conserving surgery, simple mastectomy and breast reconstruction," *Eur. J. Cancer*, Vol. 36, No. 15, 2000, pp. 1938–43.
- [3] O. Tepper, N. Karp, K. Small, J. Unger, L. Rudolph, A. Pritchard, and M. Choi, "Three-dimensional imaging provides valuable clinical data to aid in unilateral tissue expander-implant breast reconstruction," *Breast J.*, Vol. 14, No. 6, 2008 pp. 543–50.
- [4] D. Chen, I. Kakadiaris, M. Miller, R. Loftin, and C. Patrick, "Modeling for Plastic and Reconstructive Breast Surgery," Springer-Verlag, 2000, pp. 1040–1050.
- [5] Y. Kim, K. Lee, and W. Kim, "3D virtual simulator for breast plastic surgery," *Comp. Anim. Virtual Worlds*, vol. 19, 2008, pp. 515–526.
- [6] L. Roose, W. De Maerteleire, W. Mollemans, F. Maes, and P. Suetens, "Simulation of Soft-Tissue Deformations for Breast Augmentation Planning," Springer-Verlag, 2006, pp. 197–205.
- [7] L. Roose, W. De Maerteleire, W. Mollemans, and P. Suetens, "Validation of different soft tissue simulation methods for breast augmentation," *Int. Congr. Ser.*, Vol. 1281, May 2005, pp. 485–490.
- [8] J. Lee, M. Kawale, F. Merchant, J. Weston, M. Fingeret, D. Ladewig, G. Reece, M. Crosby, E. Beahm, and M. Markey, "Validation of stereophotogrammetry of the human torso," *Breast cancer basic Clin. Res.*, Vol. 5, 2011, pp. 15–25.
- [9] N. Thacker, F. Aherne, and P. Rockett, "The Bhattacharyya Metric as an Absolute Similarity Measure for Frequency Coded Data," *Kybernetika*, Vol. 34, No. 4, 1997, pp. 363–368.